



Clinical Practice Procedures: Trauma/Resuscitative clam shell thoracotomy

Policy code	CPP_TR_RCT_o823
Date	Aug, 2023
Purpose	To ensure a consistent procedural approach to resuscitative clam shell thoracotomy.
Scope	Applies to Queensland Ambulance Service (QAS) clinical staff.
Health care setting	Pre-hospital assessment and treatment.
Population	Applies to all ages unless stated otherwise.
Source of funding	Internal – 100%
Author	Clinical Quality & Patient Safety Unit, QAS
Review date	Aug, 2026
Information security	UNCLASSIFIED – Queensland Government Information Security Classification Framework.
URL	https://ambulance.qld.gov.au/clinical.html

While the QAS has attempted to contact all copyright owners, this has not always been possible. The QAS would welcome notification from any copyright holder who has been omitted or incorrectly acknowledged.

All feedback and suggestions are welcome. Please forward to: Clinical.Guidelines@ambulance.qld.gov.au

Disclaimer

The Digital Clinical Practice Manual is expressly intended for use by appropriately qualified QAS clinicians when performing duties and delivering ambulance services for, and on behalf of, the QAS.

The QAS disclaims, to the maximum extent permitted by law, all responsibility and all liability (including without limitation, liability in negligence) for all expenses, losses, damages and costs incurred for any reason associated with the use of this manual, including the materials within or referred to throughout this document being in any way inaccurate, out of context, incomplete or unavailable.

© State of Queensland (Queensland Ambulance Service) 2023.



This work is licensed under the Creative Commons Attribution-NonCommercial-NoDerivatives V4.0 International License

You are free to copy and communicate the work in its current form for non-commercial purposes, as long as you attribute the State of Queensland, Queensland Ambulance Service and comply with the licence terms. If you alter the work, you may not share or distribute the modified work. To view a copy of this license, visit <http://creativecommons.org/licenses/by-nc-nd/4.0/deed.en>

For copyright permissions beyond the scope of this license please contact: Clinical.Guidelines@ambulance.qld.gov.au

Resuscitative clam shell thoracotomy

Aug, 2023

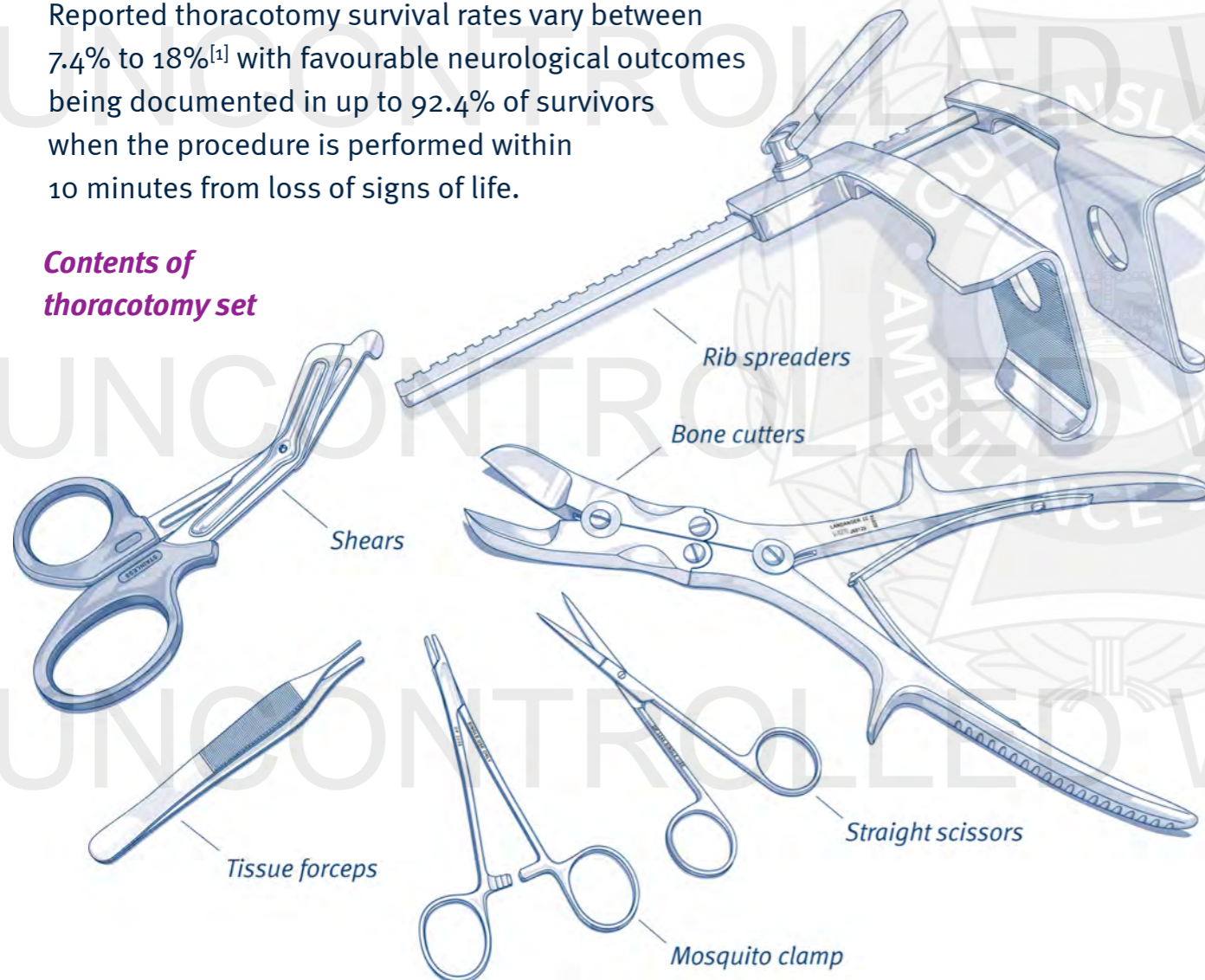
A thoracotomy is a surgically invasive procedure performed by trained physicians to maximise the chance of survival in traumatic cardiac arrest, most commonly following penetrating trauma.

Pre-hospital thoracotomy is only to be performed when the procedure is unable to be commenced in a hospital emergency department or operating theatre within 10 minutes from loss of **signs of life**.

It is essential that the decision to perform a thoracotomy is made within 20 seconds of assessing the patient and establishing the time of loss of signs of life.

Reported thoracotomy survival rates vary between 7.4% to 18%^[1] with favourable neurological outcomes being documented in up to 92.4% of survivors when the procedure is performed within 10 minutes from loss of signs of life.

Contents of thoracotomy set



Indications^[2]

Absolute indications:

- Penetrating torso trauma from a sharp instrument with loss of signs of life for less than 10 minutes
- Blunt thoracic trauma with loss of signs of life for less than 10 minutes; **AND** pericardial tamponade with cardiac activity observed on FAST ultrasound

Relative indications:

- Gunshot injury to the torso with pericardial tamponade **AND/OR** cardiac activity with loss of signs of life for less than 10 minutes
- Extremity/neck trauma with loss of signs of life for less than 5 minutes

Signs of life are defined as **any** of the following:

- Pupillary response
- Ventilator effort
- Carotid pulse
- Palpable BP
- Extremity movement
- Cardiac electrical activity.

Contraindications

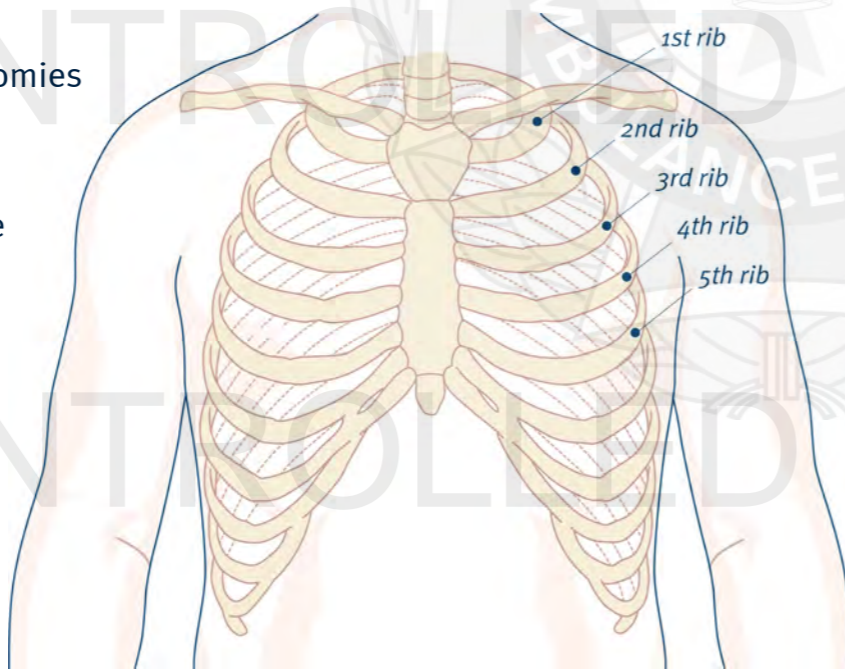
- Obvious non survivable injury
- Current cardiac output
- Loss of sign of life for longer than 10 minutes

Complications

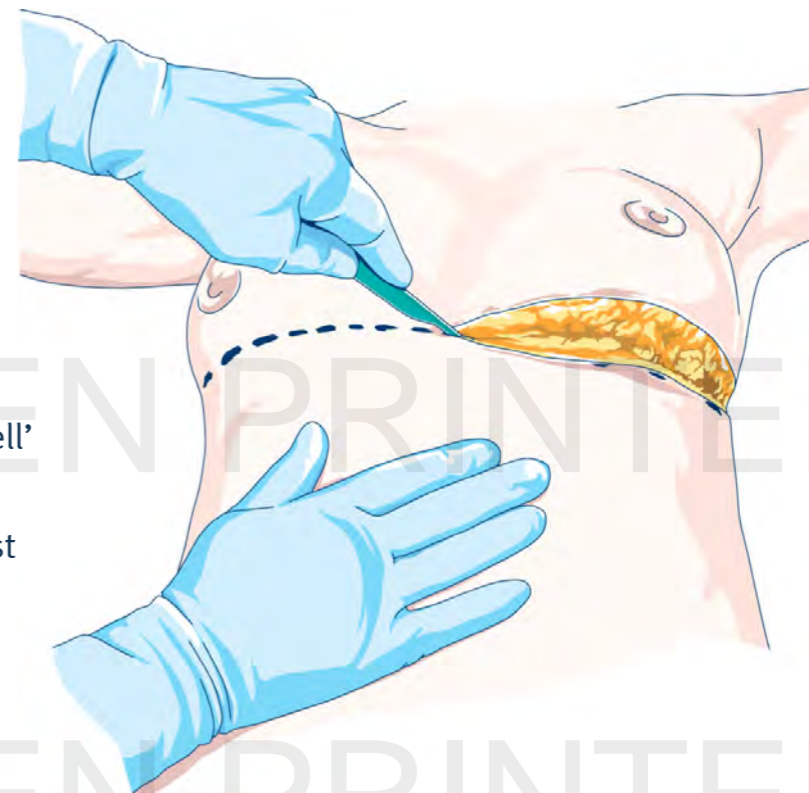
- Infection
- Transection of the phrenic nerve
- Inadvertent ligation of the coronary arteries

PROCEDURE ^[3]

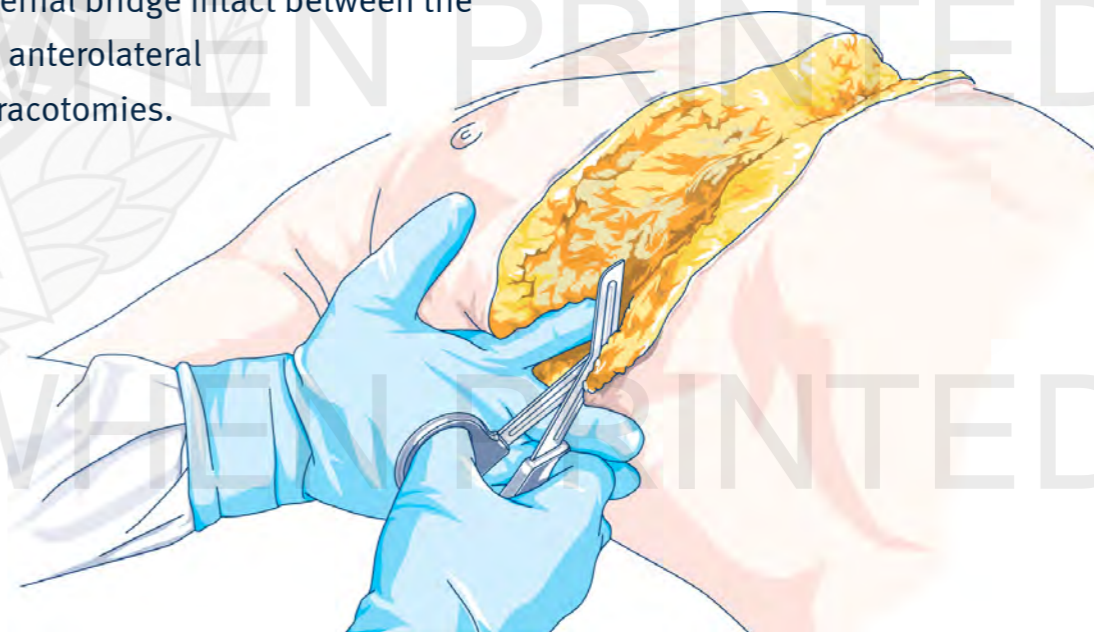1. Apply required infection control measures (refer to *QAS Infection Control Framework*).
2. Prepare the incision sites with a BD Chloraprep™ cutaneous solution applicator:
 - *Squeeze* – remove the applicator from the wrapper and hold with the sponge facing downward, gently squeeze the wings.
 - *Prime* – saturate the sponge by repeatedly pressing gently against the treatment area.
 - *Apply* – apply the solution using a gentle back-and-forth motion.
3. Apply sterile gloves over gloves already being worn.
4. Perform bilateral thoracostomies in the 4th or 5th intercostal space anterior to the mid axillary line, completing the injured side first. This is to exclude tension haemo/pneumothorax as a cause of the loss of signs of life.

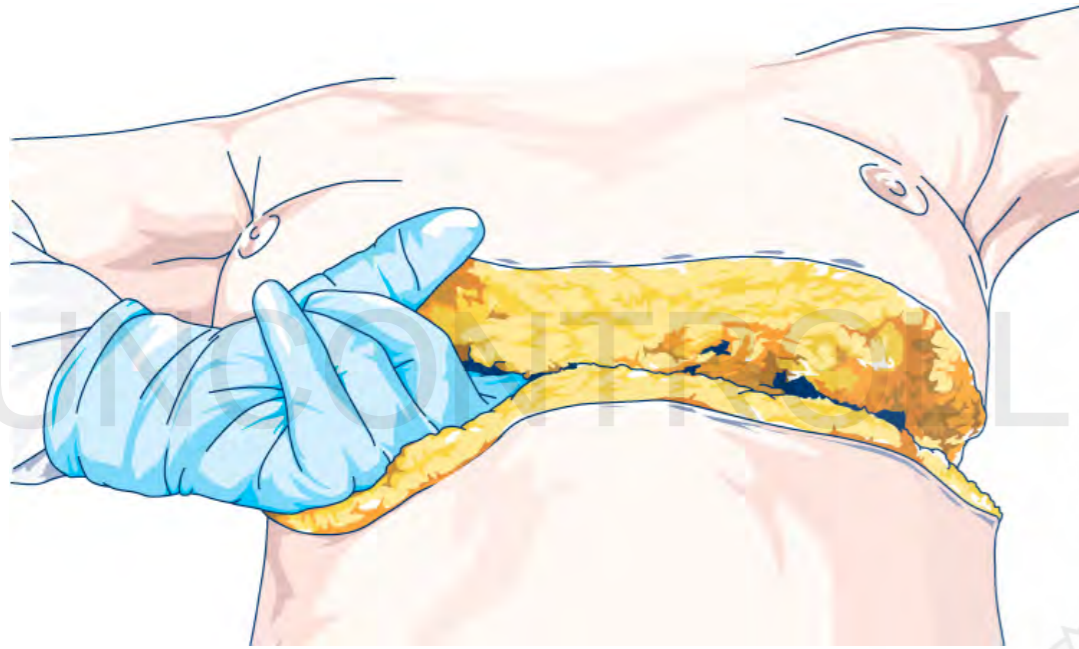


5. Connect the thoracostomies with a deep swallow shaped skin incision following the 4th or 5th intercostal space. The 'clam shell' incision should cut down to the fat/chest wall.

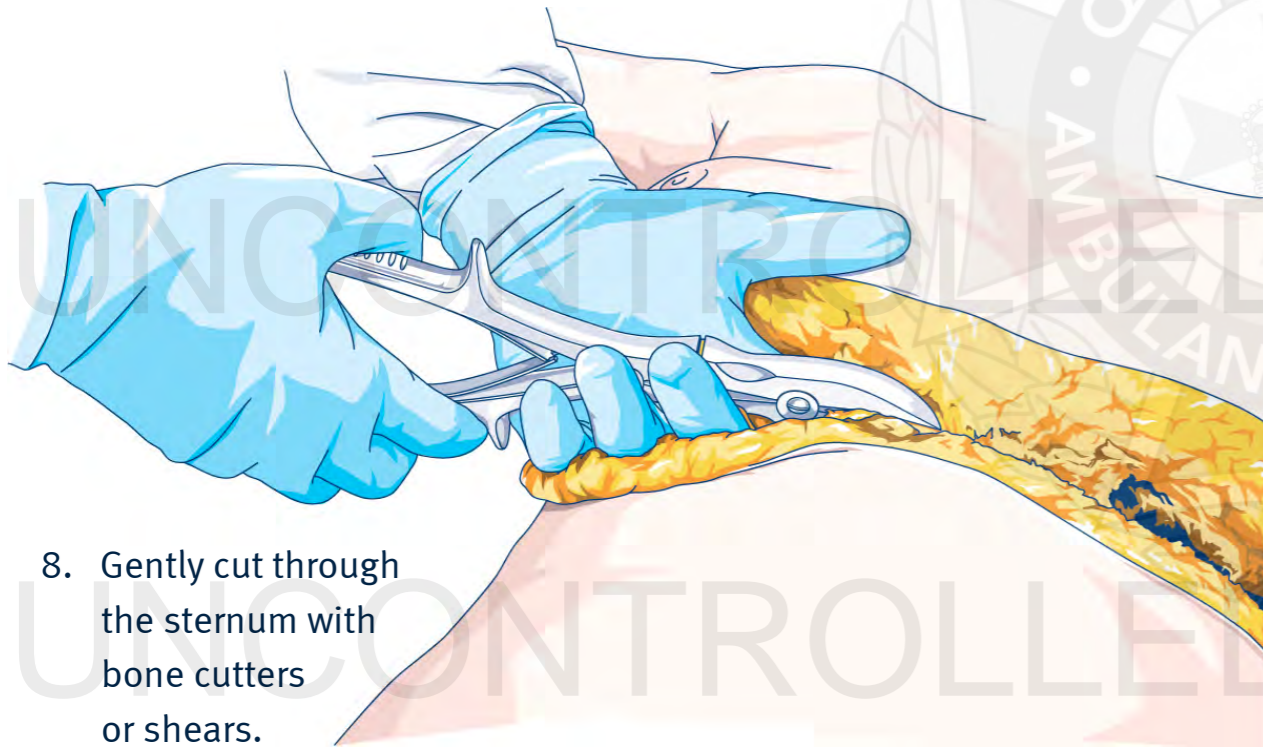


6. Gently insert sterile shears into one of the thoracostomy incisions and cut through all layers of the intercostal muscles and pleura, cutting towards the sternum. Use the pressure against the lower ribs to open up the space so as to facilitate the cutting plane. Perform this on the left and right sides leaving only a sternal bridge intact between the two anterolateral thoracotomies.



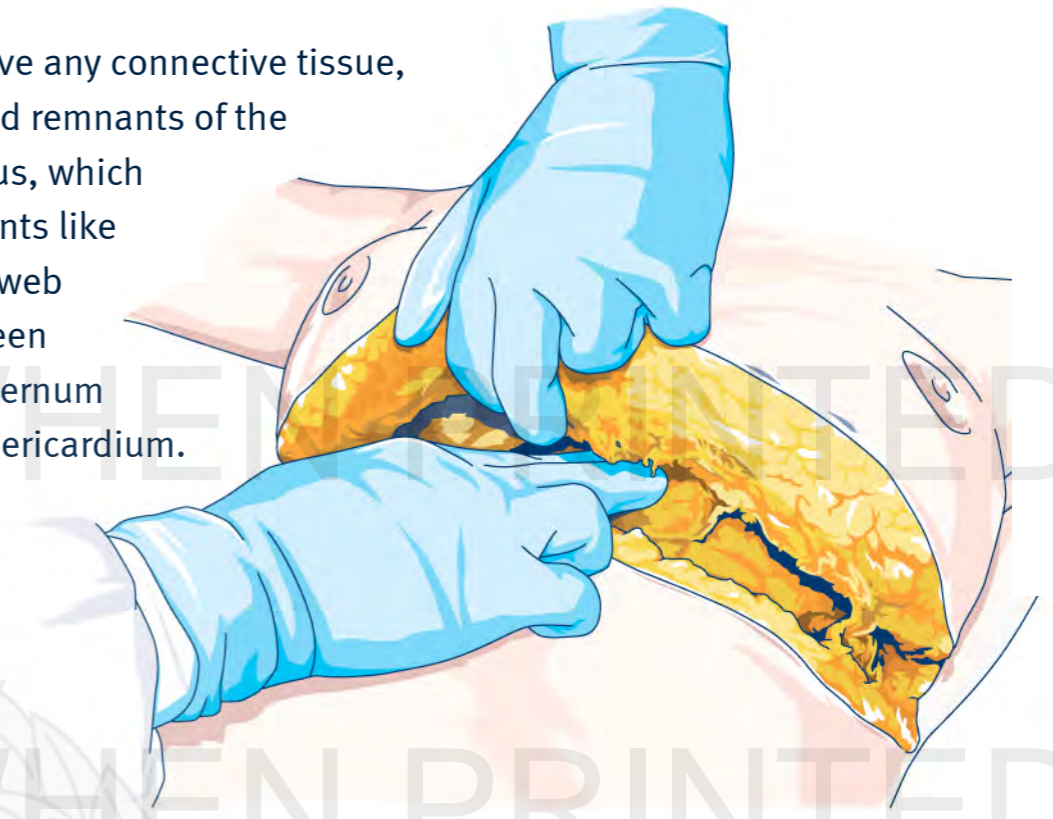


7. Perform a finger sweep under the sternum to free up any tissue, especially to ensure the pericardium is not adherent.

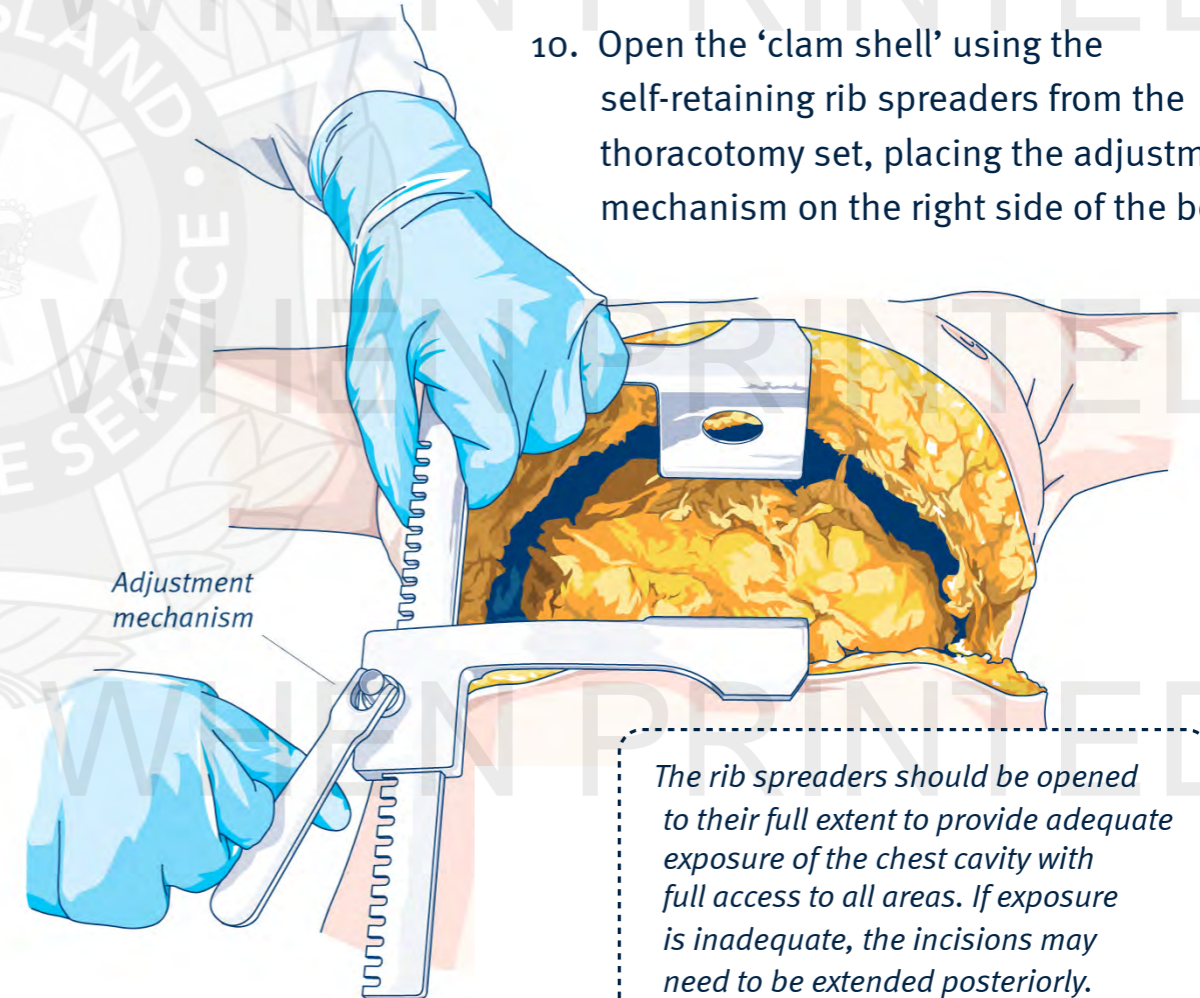


8. Gently cut through the sternum with bone cutters or shears.

9. Remove any connective tissue, fat and remnants of the thymus, which presents like a cobweb between the sternum and pericardium.



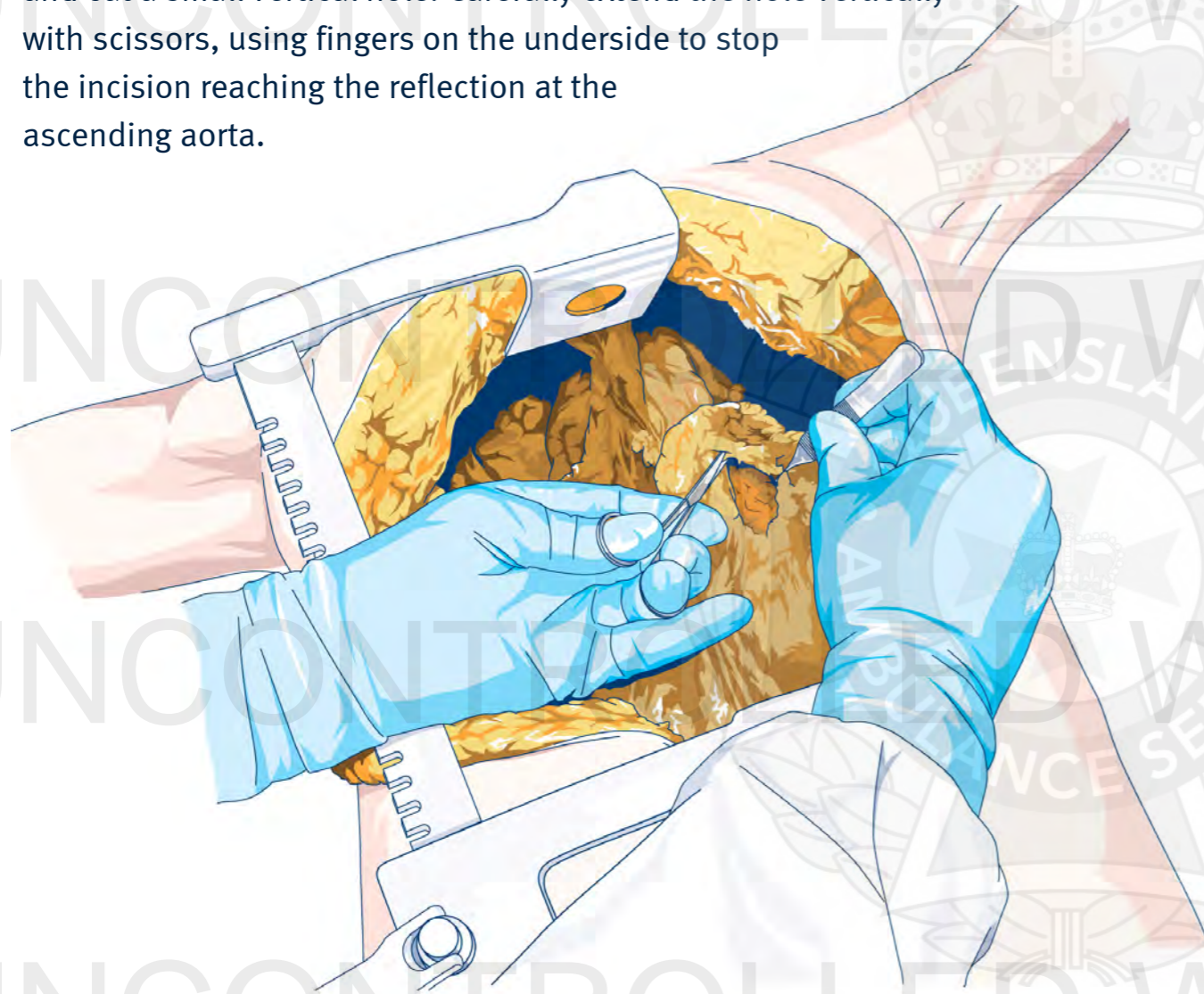
10. Open the 'clam shell' using the self-retaining rib spreaders from the thoracotomy set, placing the adjustment mechanism on the right side of the body.



The rib spreaders should be opened to their full extent to provide adequate exposure of the chest cavity with full access to all areas. If exposure is inadequate, the incisions may need to be extended posteriorly.

Procedure – Resuscitative clam shell thoracotomy

11. Identify the heart; if a tamponade is present the pericardium will look tense, enlarged and purplish/blue in colour.
12. Using forceps, raise a tent of pericardium on the anterior surface of the heart and cut a small vertical hole. Carefully extend the hole vertically with scissors, using fingers on the underside to stop the incision reaching the reflection at the ascending aorta.



13. Evacuate all the blood and clot, deliver the the heart from the pericardium and then systematically inspect the heart for the site of bleeding (including the posterior surface). The superior mediastinal structures can be kinked as the heart is reflected forward during this inspection so minimise the angle and duration of the procedure to prevent structural damage and cessation of blood flow.

14. One of **three** scenarios are now likely:

- a) The heart will begin to beat spontaneously with a return of cardiac output. In this situation any cardiac wounds should be closed (*see #13*).
- b) The heart begins to beat slowly with a considerably reduced cardiac output. In this situation wounds should be closed quickly, then attempt to improve cardiac output with supplementary internal cardiac massage and consideration for inotropic support.
- c) The heart remains in asystole. In this case, wounds should be quickly closed and then attempts made to restart the heart. Simply flicking the heart with fingers may produce a return of contractions.

If VF is present:

- In the case of coarse VF – remove the rib spreaders, close the chest, apply electrodes to the chest wall and defibrillate.
- In the case of fine VF – continue quality internal massage until coarse VF or spontaneous activity returns. Defibrillate for coarse VF as above.
- Before defibrillating ensure there are no blood pools/fluids as these may cause arcing.

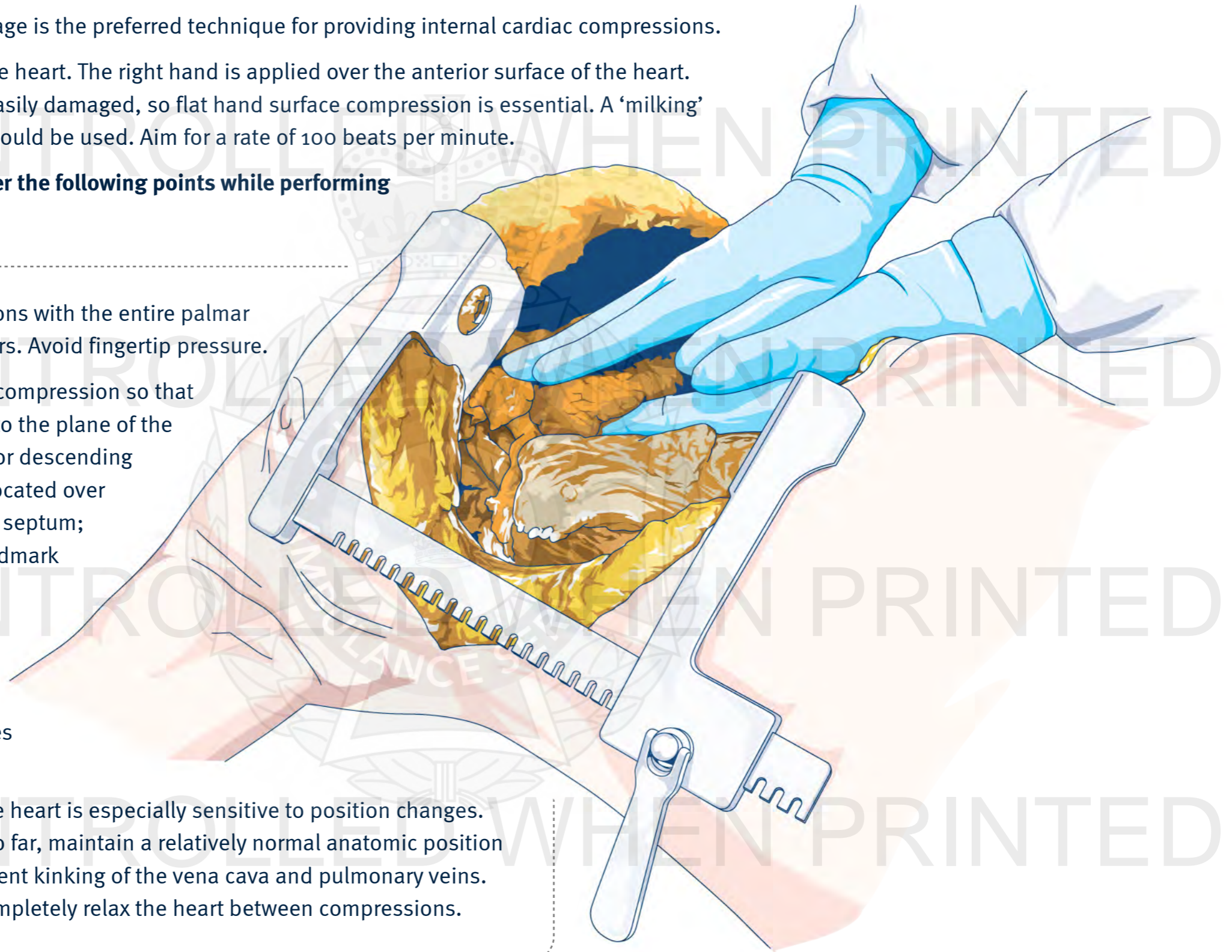
Procedure – Resuscitative clam shell thoracotomy

15. Two handed cardiac massage is the preferred technique for providing internal cardiac compressions.

Cup the left hand under the heart. The right hand is applied over the anterior surface of the heart. The heart muscle is very easily damaged, so flat hand surface compression is essential. A ‘milking’ compression technique should be used. Aim for a rate of 100 beats per minute.

It is important to remember the following points while performing cardiac compression:

- Perform compressions with the entire palmar surface of the fingers. Avoid fingertip pressure.
- Adjust the force of compression so that it is perpendicular to the plane of the septum. The anterior descending coronary artery is located over the interventricular septum; this is a helpful landmark to orient your hand properly.
- Position the fingers so that the coronary arteries are not occluded.
- Venous filling of the heart is especially sensitive to position changes. Without lifting it too far, maintain a relatively normal anatomic position of the heart to prevent kinking of the vena cava and pulmonary veins. It is essential to completely relax the heart between compressions.



Procedure – Resuscitative clam shell thoracotomy

16. Control any bleeding:
 - a) Small wounds of 1 cm or less can be left if there is limited blood loss, however if bleeding is significant they should be sutured /stapled or occluded with a finger. Be careful not to insert a finger into the incision as this may extend the wound.
 - b) Wounds adjacent to coronary arteries should be treated with caution. If the artery is distal then it and the distal myocardium can be sacrificed if necessary, otherwise either a mattress suture should be used or occlude the wound with a finger. Skin staples should be used primarily for temporary wound closure. Handheld 1/0 silk is also available to insert interrupted sutures if stapling is not successful.
 - c) Although the use of Foley catheters may be considered, placement may cause the wound to extend. Plugging the wound with a finger or pack may be preferable.
 - d) Ideally, a second operator should provide digital pressure to the descending aorta.
17. Fluid load the patient once bleeding sites have been stemmed. The preferred fluid is warmed blood.
18. Internal cardiac massage and repeated adrenaline (epinephrine) doses should be continued until appropriate myocardial activity is achieved.
19. If the procedure is successful, the internal mammary arteries may begin to bleed and require closure.
20. Anaesthetise the patient as required; be aware that these patients are extremely sensitive to any sedative or analgesic medications.
21. If there is no cardiac output 20 minutes after commencement of the thoracotomy, resuscitation efforts should be ceased. Once the rib spreaders have been removed, the wound is to be gently packed with a saline soaked combine (90 cm x 20 cm) and covered with two 3M loban™ occlusive dressings.

Additional information

- The use of medical gloves is not a substitute for hand hygiene. Hand hygiene should be performed before donning and doffing medical gloves and immediately before and after any procedure.
- Eye protection must be worn by all clinicians. The potential of blood and body fluids exposure (especially in the face any eyes) during this procedure is **HIGH**.
- The clinician must ensure that all chest decompression devices (cannulas and Pnuemodarts®) are removed prior to inserting a finger into the thoracotomy incision.
- Consideration must be given to the possible psychological effects on the patient, clinicians, emergency services staff and bystanders who are involved in or exposed to witnessing this procedure.
- Securing an airway with an ETT or SAD, or gaining IV access should not delay performing a thoracotomy. These tasks should be delegated to other paramedics at the scene.^[4-6]
- If cardiac output is restored following thoracostomies, the thoracotomy procedure must be immediately ceased.
- Bleeding from the Mammary Arteries can be controlled by the application of mosquito forceps.
- The role of pre-hospital thoracotomy for blunt traumatic cardiac arrest is reserved for patients with a pericardial tamponade confirmed by ultrasound, where thoracic aortic compression may be of benefit. Routine thoracotomy for blunt trauma cardiac arrest is yet to show any survival benefit.^[3,7]
- A resuscitative clam shell thoracotomy does not increase systemic or thoracic complications when compared to a left anterolateral approach.^[8]
- The *rib spreaders* and *bone cutters* are **re-usable** medical instruments that require reprocessing and sterilisation in accordance with the *QAS Infection Control Framework*.